

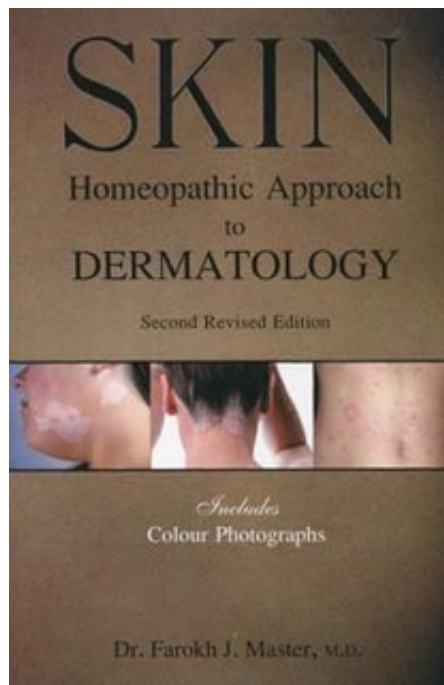
Farokh J. Master Skin

Reading excerpt

[Skin](#)

of [Farokh J. Master](#)

Publisher: B. Jain



<http://www.narayana-verlag.com/b4592>

In the [Narayana webshop](#) you can find all english books on homeopathy, alternative medicine and a healthy life.

Copying excerpts is not permitted.

Narayana Verlag GmbH, Blumenplatz 2, D-79400 Kandern, Germany

Tel. +49 7626 9749 700

Email info@narayana-verlag.com

<http://www.narayana-verlag.com>



Diagnosis

- Demonstration of typical lesion - polyhedral, firm, violaceous (may be difficult to detect in dark skinned people), flat topped papules with Wickham's striae and very thin adherent scales.
 - Distribution on flexors, genitalia and mouth.
 - Pruritus.
 - A chronic course.
- A typical histology.

Differential Diagnosis

The only differential diagnosis to be considered in a typical case is that of lichenoid eruptions induced by drugs or colour developer, and this must be based on the history. Less typical cases of LP may be mistaken for plane warts, eczematous eruptions with lichenification from scratching, pityriasis rosea, lichen simplex chronicus and other lichenoid eruptions such as lichen amyloidosis (papular). The occasional cases of LP without itching must be distinguished from secondary syphilis. The differential diagnosis of the special variants has already been mentioned. In any case of doubt, a biopsy should establish the diagnosis. The mucous lesions of lichen planus must be differentiated from the lesions of leukoplakia, the mucous patches of syphilis and aphthous stomatitis. On the scalp it must be distinguished from discoid lupus erythematosus, pseudo-pelade, favus, etc.

Other Lichenoid Eruptions

LICHEN SCROFULOROSUM

It is an uncommon questionable tuberculide. It affects children with or without systemic tuberculosis. The shoulders and trunk are the sites involved. Clinically, the lesions consist of patches of grouped, firm, follicular, bluish-red indolent papules with central spines. It itches slightly. Histopathology is tuberculoid. Tuberculin test is negative.

LICHEN SPINULOSUS

It is characterized by pinhead sized, follicular, flesh coloured papules with horny spines. The papules are grouped in patches. Children are commonly affected. Sites of affection are the abdomen, buttocks and legs. The condition is asymptomatic, and clears up with a good nourishing diet containing plenty of animal fats, extra vitamins, tonics and the local application of animal fats or cod liver oil.

LICHEN SYPHILITICUS

Follicular papules with induration; slight itching; lymphadenopathy mucous patches and a history of exposure. The VDRL is positive,

LICHEN SIMPLEX CHRONICUS

Lichenification or neurodermatitis is another term. Affecting more commonly neurotic people who are prone to chronic scratching and rubbing of skin under stress and anxiety. It is common amongst young people and menopausal women. The integument becomes thickened, infiltrated and pigmented; the criss-cross markings become more prominent. Margins are irregular but usually well defined. There may be one or several localized patches. Occasionally an extensive disseminated variety is seen.

Sites: Nape of neck, arms, ano-genital area, scrotum, back of knees, legs and ankles.

Chronic eczemas may become lichenified through constant scratching. Lichenification is a prominent feature of atopic eczema. In the dark Indian skin, lichenification occurs early. Differential diagnosis is from lichenified eczemas, atopic dermatitis, lichen planus hypertrophicus.

LICHENOID DRUG ERUPTIONS

These occur commonly in the tropics and in dark skinned people. An idiosyncrasy to certain drugs, e.g. brufen (NSAID) arsphenamine, gold, chloroquine, onepacrine, hydroxychloroquine,

quinine and certain phenothiazine derivatives, para-amino-salicylic acid, thiazide diuretics and aminophenazole (Daptazole) may result in lichenoid eruption which may simulate lichen planus. Contact with chemicals used in the processing of coloured photographic films may, in sensitized individuals, produce similar eruptions.

LICHEN NITIDUS

It consists of discrete, pink or flesh coloured, asymptomatic papules grouped in patches. The typical sites are the genitalia, inner sides of thighs, lower abdomen and at times wrists. It is a benign disease.

LICHEN STRIATUS

An uncommon form occurring in children. It usually affects upper limbs and occasionally the legs. Lesions consist of flesh colored or darker lichenoid papules arranged in a linear fashion, usually unilateral and along the long axis of a limb. Streak may be only a few centimeters in length or extend along the long axis suggesting a linear naevus. Histopathology is non-specific. No active treatment is necessary as the eruption has a tendency to disappear spontaneously.

LICHEN URTICATUS

Synonym: Papular urticaria. Refer to chapter of Urticaria.

LICHEN AMYLOIDOSES

Localized variety of primary cutaneous amyloidosis. Itching papules, nodules or plaques, yellowish brown in color, combined with pigmentation. A biopsy and Congo Red test help in diagnosis.

LICHEN SCLEROSUS ET ATROPHICUS

It is essentially confined to the cutaneous portion of the vulva, anogenital region, trunk and shoulders. Irregular, whitish papules and plaques with keratotic plugs or central dellings characterize it; later white tissue paper like wrinkled patches develop. Minimal pruritus.

Histology

Hyperkeratosis, follicular plugging, epidermal atrophy, band of hyalinized collagen below the epidermis, dilated capillaries and a band of round cell infiltration. It is a chronic disease, allopathic treatment being unsatisfactory.

LICHEN MYXEDEMATOSES

A very rare but definite entity, practically independent of thyroid pathology. Lesions consist of discrete, localized papular, annular or discoid, lichenoid plaques. This is associated with infiltration and at times lymphedema. Itching is only minimal. General health is not affected. Basal metabolic rate, erythrocyte sedimentation rate and other tests for metabolic defect are nominal except the blood lipids may show slight change. Thyroid extract may benefit an occasional patient.

Prognosis

Occasional cases clear in a few weeks, but most acute and subacute attacks will last 6-9 months unless treated with systemic corticosteroids or the potent topical steroids. The first feature to disappear is itching. The papule then flattens, but is often replaced by a corresponding area of pigmentation. If hypertrophic patches develop, they are likely to persist for many more months, and occasionally for 20 years or more. The development of large, annular lesions is also a poor prognostic sign in terms of longevity of the disease. When hair fall occurs, it is usually permanent. Mucous membrane lesions clear more slowly than those on the skin and may remain visible for years after all evidence of the skin lesions has cleared.

HOMEOPATHIC APPROACH TO LICHEN PLANUS

Lichen planus should be considered as a constitutional disorder and not merely a local disease. Relapses and remissions characterize the disease and the course of the illness is chronic. Hence, case should be taken to treat the disease at its earliest, so that we can

give relief to the patient from the pruritus, which is one of the most annoying symptoms of the disease.

Psychogenic stress is known to induce the relapse in many individuals; hence, while taking the history of the patient, it is important to discuss the mental state in great detail. At no cost corticosteroid should be advised to the patient. If he is already on corticosteroid, then it should be tapered off at the earliest. Soothing lotion preferably calendula mother tincture 1:10 dilution should be advised. The following points should be considered while taking the history:

1. Psychosomatic aspects of the patient.
2. Pruritus should be enquired into in detail with its modalities and concomitant.
3. Lichen planus is known to have many variants hence sound knowledge of its manifestations should be known to the treating physician. Psychotherapy in obstinate cases can be given along with homeopathic drugs.

Certain variants of lichen planus and lichen striatus are known to disappear spontaneously. Hence, one should be aware of the natural course of the disease.

Drugs given below are found useful in cases of lichen planus. The reader is advised to refer the therapeutics of Eczema and Psoriasis for its characteristic symptoms.

Some Important Homeopathic Remedies

agar, alum, am-m, anac, ant-c, anan, apis, ars, ars-i, bell, bov, bry, calad, castn-v, chinin-ar, dulc, iod, jug-c, kali-ars, kali-bi, kali-i, kreos, led, lye, mere, merc-s, nabal, nat-c, plan, phyt, rumx, sep, sars, staph, sulph, sul-i, til.

REPERTORY


- Skin, eruptions

Lichen: Agar, anthraco, apis, ars, ars-i, aur, dulc, jug-c, mang, phyt, rhus-t, rumx, sulph, til.

Lichen planus: Sul-i, sulph, syph.

- Papular: Allox, aur, calc, caust, cham, cycl, gels, grin, hippoz, hydrc, iod, kali-bi, kali-c, kali-i, kali-s, lye, mere, narc-ps, petr, phos, pic-ac, psor, sep, sil, sulph, syph, thiop, zinc.
- Itching: Allox, beryl.

Flat: Am-c, ang, ant-c, ant-t, ars, asaf, bell, carb-an, euph, lach, lye, mere, nat-c, nit-ac, petr, ph-ac, phos, puls, ran-b, sel, sep, sil, staph, sulph, thuj.



Farokh J. Master

[Skin](#)

Homeopathic Approach to Dermatology

1036 pages, pb
publication 2014



order

More books on homeopathy, alternative medicine and a healthy life www.narayana-verlag.com