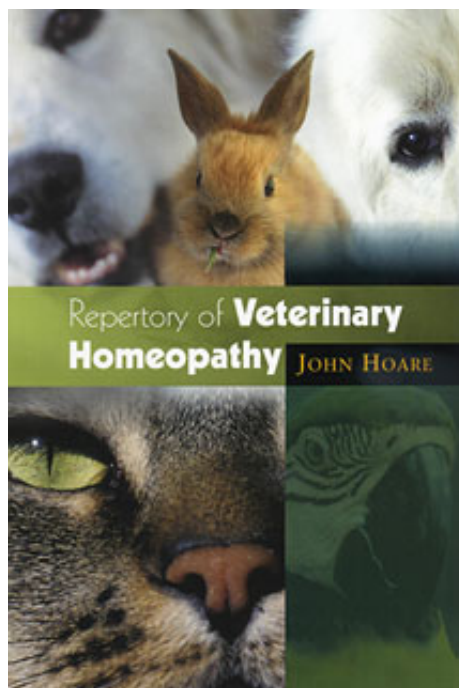


# John Hoare

## Repertory of Veterinary Homeopathy

Reading excerpt  
[Repertory of Veterinary Homeopathy](#)  
of [John Hoare](#)  
Publisher: Saltire Books



<http://www.narayana-verlag.com/b12675>

In the [Narayana webshop](#) you can find all english books on homeopathy, alternative medicine and a healthy life.

Copying excerpts is not permitted.

Narayana Verlag GmbH, Blumenplatz 2, D-79400 Kandern, Germany

Tel. +49 7626 9749 700

Email [info@narayana-verlag.com](mailto:info@narayana-verlag.com)

<http://www.narayana-verlag.com>



# THE EYES

## **Eyelids**

Rubrics exist in the EYE section of the Repertory for inflammation and swelling of the lids; eruptions and tumours on the lids; and paralysis of and twitching of the lids. In addition there are many rubrics concerned with eruptions, discharges etc. Where there is an accumulation of discharges, or obvious inflammation, bathing with a 10% Solution of Euphrasia Ticture can be used to support the main remedy.

*Swollen and/or inflamed eyelids* (see Table 4.1)

These are usually due to infections of the skin and glands of the lids themselves. It can also be due to an allergic reaction resulting in oedema of the lids.

Masses on the margins of the lids are dealt with later.

*Warts, Styes and Other Masses on Lids* (see Tables 4.2 and 4.3)

Rubrics include:

- EYES: Condylomata, warts and sub rubrics.
- EYES: Nodules, lids and sub-rubrics.
- EYES: Styes, and sub-rubrics.
- EYES: Tumours; lids. Sub-rubrics of this include cysts and nodules.

*Cracked and fissured lids* (see Tables 4.4 and 4.5)

Rubrics and sub-rubrics exist for:

- EYES: Cracks; canthi.
- EYES: Cracks; lids.

## 22 Repertory of Veterinary Homeopathy

*If necessary look at:*

Lachrymation and Eyes, Discharges.

*Entropion, trichiasis and/or distichiasis (see Tables 4.6 and 4.7)*

Entropion is the inturning of the eyelid which can cause the eyelashes to rub against the cornea and so inflame it.

The rubric is:

- EYES: Turning out of lids.

Distichiasis is the presence of a double row of lashes, one of which rubs against the cornea. If the condition is mild, simple plucking can keep things under control. If it is serious, corrective surgery is needed. Some remedies can help in mild cases, or make it possible to defer surgery until a young animal is fully grown. Borax veneta is the usual remedy tried, but the others listed can help if they are used constitutionally.

### *Ectropion*

Rubrics: This is found as:

- EYES: Turning out of lids, ectropion.

If it is causing trouble, it is normally a surgical condition. Staphysagria and Borax are said to be helpful in very mild cases.

There is no Table for this condition because the differentiation between the two remedies is easy.

### **Outer Eyeball**

For the purposes of this book, this includes the conjunctiva, the sclera and the cornea.

These structures appear in sub rubrics of Inflammation and Pain. There is also Swelling - conjunctiva.

*Sore and inflamed eyes without corneal ulceration*  
(see Tables 4.8-4.10)

This includes 'conjunctivitis', 'scleritis' and 'keratin's'.

*Remember:* Look for the presence of any foreign body such as a grass seed; and to check (stain) for ulcers when necessary.

*Corneal Ulceration* (see Tables 4.11 and 4.12)

Rubrics are found under:

- Eye: Cornea: ulceration and its sub-rubrics.

*Corneal opacities* (see Table 4.13)

There is usually some form of 'cloudiness' associated with keratitis and corneal ulcerations. This is covered in those sections. This section covers spots, scars etc that are usually the result of past infections and trauma.

Rubrics: Suitable rubrics are found in the Eye Section under:

- EYES: Opacity; cornea and its sub-rubrics.
- EYES: Spots, specks; cornea.
- EYES: Spots, specks, scars; cornea.

**Lachrymal glands and ducts** (see Table 4.14 and 4.15) The

glands may malfunction and the cornea become too dry.

When the Ducts are blocked or absent, tear staining occurs at the inner canthus. Homeopathy cannot help when the ducts are absent, only when they are present.

Tear-staining may also result from an overproduction of tears. It can be differentiated from blocked ducts by staining with fluorescein. Absent ducts require surgery.

Rubrics can be found for swelling, inflammation and stricture of the lachrymal ducts in the Eye Section.

Rubrics also exist for Fistula lachrymalis.

*'Dry Eye.'* *Cornea not glistening* (see Table 4.16)

This is due to a malfunction of the lachrymal gland. Artificial tears help to prevent damage caused by the drying of the cornea. The listed remedies may help to prevent the need for surgery.

### **Inner structures of the Eye**

These are the Lens, and the Uvea which consists of the iris, ciliary body and choroid and the Retina.

*Opacity of the lens - Cataract* (see Tables 4.17 and 4.18)

Rubric: The main rubric is:

- EYES: Cataract; opacity of lens.

There are many sub-rubrics.

*Whole eye inflamed and painful* (see Tables 4.19 and 4.20)

The client is unlikely to differentiate between Choroiditis, Uveitis, Iritis etc. These are taken together here as Ophthalmitis as the listed remedies usually cover all these conditions.

Rubrics include:

- EYES: Inflammation; choroid/iris and sub-rubrics.
- EYES: Discolouration: redness; choroid/iris/sclera/retina and sub-rubrics.
- EYES: Injuries of eyes and sub-rubrics.
- EYES: Adherent: pupils, cornea and iris adhering.
- EYES: Miosis and Mydriasis.

*Annular/Peripheral vascular infiltration of Cornea*  
(see Table 4.21)

Glaucoma usually presents as a very painful eye often with a peripheral fringe of blood vessels infiltrating the cornea. The cornea itself may become cloudy and the retina damaged. Pressure can be measured with a tonometer, and the drainage angle of the examined using a gonioscope if necessary. Surgery is often needed to increase drainage, but the listed remedies may help.

Rubrics and subrubrics exist for:


- EYES: Glaucoma.
- PAIN: Glaucoma.

*Loss of vision - Retinal problems (see Table 4.22)*

Animals are not usually brought to the surgery because of blindness except in the case of retinal degeneration due to age or trauma. Young dogs are sometimes presented with vision difficulties due to PRA. PRA is not curable, but can be slowed. Trauma can be treated with varying degrees of success.

Rubrics exist for:

- EYES: atrophy; retina.
- EYES: degeneration; retina.
- VISION: loss of vision, blindness; atrophy of retina, from.



John Hoare

## [Repertory of Veterinary Homeopathy](#)

224 pages, pb  
publication 2012



**order**

More books on homeopathy, alternative medicine and a healthy life [www.narayana-verlag.com](http://www.narayana-verlag.com)