

Chauhan / Gupta

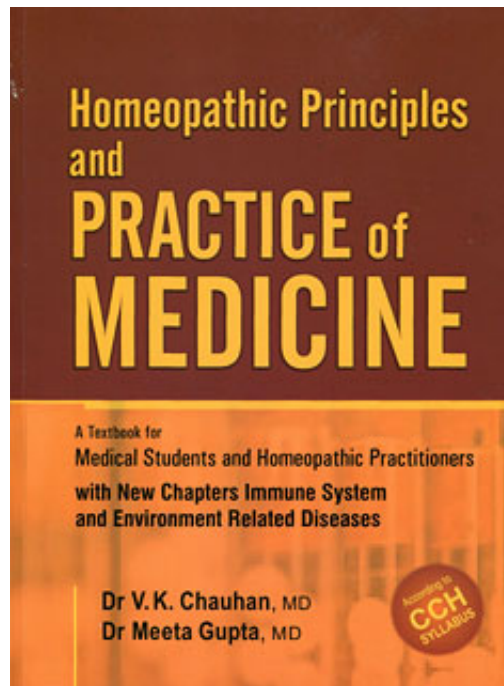
Homeopathic Principles and Practice of Medicine

Reading excerpt

[Homeopathic Principles and Practice of Medicine](#)

of [Chauhan / Gupta](#)

Publisher: B. Jain



<http://www.narayana-verlag.com/b5403>

In the [Narayana webshop](#) you can find all english books on homeopathy, alternative medicine and a healthy life.

Copying excerpts is not permitted.

Narayana Verlag GmbH, Blumenplatz 2, D-79400 Kandern, Germany

Tel. +49 7626 9749 700

Email info@narayana-verlag.com

<http://www.narayana-verlag.com>



MEDICAL TREATMENT**Symptomatic**

- Arsenicum iodatum.
- Kali bichromicum.
- Kali hydriodicum.
- Kali muriaticum.
- Lemna minor.
- Sambucus.
- Sanguinaria.
- Silicea.
- Sticta.
- Teucrium.

Intercurrent

- Calcarea carbonica.
- Lycopodium.
- Natrium muriaticum.
- Nux vomica.
- Phosphorus.
- Pulsatilla.
- Sepia.
- Thuja.

SINUSITIS

Acute or chronic inflammation of mucosal lining of paranasal sinuses, most commonly maxillary sinus.

CLINICAL FEATURES**Symptoms**

- Fever (during acute stage).

Pain

- Cheek and infra-orbital region (maxillary sinusitis).
- Frontal headache (frontal sinusitis).
- Nasal bridge, behind eyes (ethmoidal sinusitis).

Nasal discharge

- Tenacious.

ETIOLOGY*Predisposing and precipitating causes*

- Nasal, pharyngeal or dental infection.
- Nasal obstruction.
- Deviated nasal septum.
- Hypertrophied turbinates.

General diseases

- Measles.
- Influenza.
- Whooping cough.
- Environmental
- Poorly ventilated houses.
- Overcrowding.
- Lowered body resistance.
- Exposure to extreme cold.
- Nasal douches during early stages of inflammation
- Excessive blowing of nose during acute infection

- Yellowish-green muco-pus.
- Pain and discharge worse on stooping.
- Breath offensive, if foetid discharge.
- Post nasal drip, which irritates.
- Patient has to clear his throat frequently,

Nasal obstruction

- Of variable degree.
- Slowly progressive.
- Difficult hearing (due to eustachian catarrh)
- Nasal twang of voice.
- Anosmia or unpleasant odour.
- Bleeding from nose.

Signs

- Tenderness over affected sinus on applying pressure.
 - Anterior rhinoscopy
- Nasal mucosa red, oedematous.
- Mucopurulent discharge middle meatus running down to pool on floor of nasal cavity.

Posterior rhinoscopy

- Pus in posterior nares.
- Polypi may be found in conchae.

COMPLICATIONS

- Osteomyelitis.
- Orbital cellulitis.
- Mucocoele.
- Bronchitis.

INVESTIGATIONS

x-Ray of paranasal sinuses may show

- Mucosal thickening.
- Early polyp formation.
- Homogenous haziness, with fluid levels in infected sinus.

PROGNOSIS

- Good with treatment.
- Recurrences are common.

MIASMATIC CLEAVAGE

- Predominant sycotic disorder.

THERAPEUTIC AIM

- To cure.

GENERAL MANAGEMENT

- Rest in warm, well ventilated room during acute stage.
- Steam inhalation.
- Treat predisposing cause.
- Improve general health.
- Valsalva manoeuvre for eustachian catarrh.

MEDICAL TREATMENT

Symptomatic

- Hydrastis.
- Kali bichromicum.
- Kali hydriodicum.
- Kali muriaticum.

- Natrum muriaticum.
 - Nux vomica.
 - Pulsatilla.
 - Sepia.
 - Silicea.
- Eustachian catarrh*
- Kali muriaticum.
 - Mercurius dulcis.
 - Pulsatilla.
 - Silicea.

Kali iodatum: Colds from every exposure from damp. Nose red, swollen, acrid watery discharge. Eyes smart and lacrymate. Catarrhal headaches with inflammation of mucous membrane of frontal sinuses, eyes, throat and chest. Forehead heavy, dull and stupid. Violent sneezing, eyes bloated, profuse lachrymation. Violent acrid coryza. Nose tender, face red, uneasy. Tongue white. Nasal voice; violent thirst.

Mercurius solubilis: Creeping chilliness in the beginning of a cold. Much sneezing, fluent discharge, corrosive. Acrid, offensive matter flows from nose greenish, foetid pus. Nose red shining. Catarrhal inflammation of frontal sinuses. Hoarse voice, dry, rough, tickling cough, feels bad in a warm room, yet cannot bear the cold. Taste sweet, salty, metallic, putrid. Creeping chilliness. Profuse offensive sweats, and worse from sweating. Swollen flabby tongue, tooth notched. Offensive breath, offensive salivation.

Pulsatilla: Better adapted to nervous, timid, young weepy female, craves sympathy, craves cold air, better motion. Old catarrh with loss of smell, thick yellow discharge, better in open air. Stuffed up at night and copious flow in the morning. Fluent in open air; stopped up in house.

Kali bichromicum: Catarrh with thick yellow or greenish, ropy, stringy mucous discharges, or tough and jelly like. Discharge offensive. Adherent mucus, which can be drawn out into long strings. Plugs in nostrils, dryness of nose with pressive

pain at root of nose, which can be covered by a coin.

Intercurrent

Tuberculinum Personal or family history of tuberculosis. Always catching cold. Always tired. Worse in warm room.

Short indications

- Early state: Bell, or Merc 30
- Headache. Thick purulent, blood stained discharge: Kali-bi. 30
- Right sided sinusitis with right headache: Sang.
- Left sided affection: Spig.
- Sensitive to cold > wrapping head: Sil.30
- Discharge thick yellow green blood stained: Aur-m 30 4hourly.

Reference: Annual Report 2001 - 2002 CCRH.

Disease related clinical trial, in general area to evaluate the action of homeopathic drugs in Sinusitis.

Observation

The following medicines in varying potencies helps in improving and achieving symptomatic relief:

- Belladonna.
- Natrium muriaticum.
- Hepar sulphuris.
- Pulsatilla.

Reference: Annual Report 2001 - 2002 CCRH.

Drug related clinical trial, in tibal area to evaluate the action of following drugs on sinusitis. Anemopsis California, Anthemis nobilis, Aurum muriaticum, Justicia adhatoda, Lemna minor, Mentholum, Quillaya, Sanguinarium nitricum, Saponaria, Sinapis nigra, Theridion.

Observation

The most prescribed of assigned medicines

- Justicea adhatoda.
- Lemna minor.
- Sinapis nigra.

NASAL POLYP

Pedunculated hypertrophied and oedematous mucosa of nose or paranasal sinuses.

ETIOLOGY

- Exact cause is not known.
- Predisposing causes*
- Chronic naso-pharyngeal allergy.
- Chronic bacterial and viral infections.
- Vasomotor disturbances.

CLINICAL FEATURES

Symptoms

- Onset insidious.
- Nasal obstruction, unilateral or bilateral.
- Anosmia.
- Epiphora.
- Post nasal drip.
- Snoring.
- Nasal twang.
- Sneezing with watery or muco-purulent discharge.
- Headache.

Signs

Anterior rhinoscopy

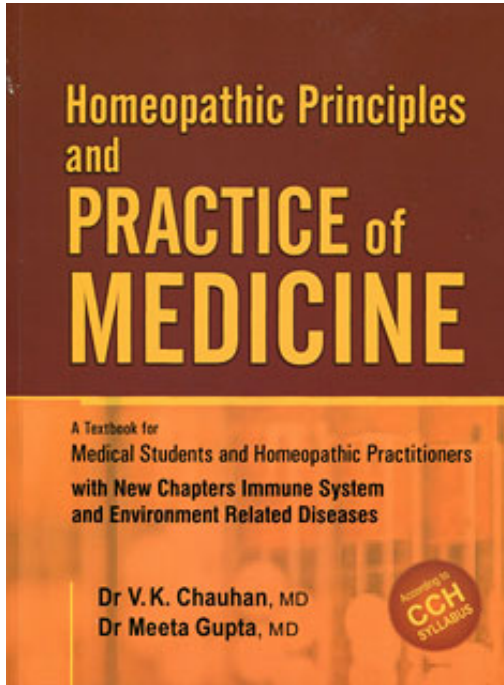
- Reveals ethmoidal polypi.
- Bilateral.
- Multiple.
- Pale, oval, appear as bunch of grapes.

Posterior rhinoscopy:

- Reveals antro-choanal polyp.
- Unilateral.
- Single.
- Greyish-blue, rounded.

COMPLICATION

- Long standing polyps result in widening of nasal soft tissues.

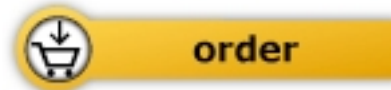

Chauhan / Gupta

[Homeopathic Principles and Practice of Medicine](#)

A Textbook for Medical Students and Homeopathic Practitioners

1238 pages, pb
publication 2012



More books on homeopathy, alternative medicine and a healthy life www.narayana-verlag.com