


P.C. Majumdar,MD Bed-Side Medicine

Reading excerpt

[Bed-Side Medicine](#)
of [P.C. Majumdar,MD](#)

Publisher: B. Jain



<http://www.narayana-verlag.com/b6002>

In the [Narayana webshop](#) you can find all english books on homeopathy, alternative medicine and a healthy life.

Copying excerpts is not permitted.

Narayana Verlag GmbH, Blumenplatz 2, D-79400 Kandern, Germany

Tel. +49 7626 9749 700

Email info@narayana-verlag.com

<http://www.narayana-verlag.com>



Malignant Hypertension

Malignant hypertension is a clinical condition, the *result of very high blood pressure of any origin, essential, renal or endocrine.*

PATHOLOGY.—Although the exact mechanism is not known, when the blood pressure rises very high, there is intense focal vasoconstriction causing vascular necrosis and perivascular tissue damage especially in the brain, retina, kidneys and other viscera. In essential hypertension, the phases of retinal haemorrhage, encephalopathy, heart failure or haematuria may be associated with progressive renal arteriolar damage and the latter further raising the blood pressure and maintaining it high, for a long time, establishes a vicious cycle of progressive severer damage.

(a) In a larger number of cases, the subjects often male are between 30 or 40 years without obvious symptoms of hypertension. Malignant phase suddenly appears, (b) Others, of age of 60 or over, have hypertension for several years and the malignant phase slowly appears.

In this, compared with benign hypertension, arteriolar degeneration is more quick and greater and is of the nature of *fibrinoid necrosis of the arterioles*. This is best seen in the kidneys : the afferent arterioles of the glomeruli are necrosed and interlobular arteries show endarteritis : this causes focal necrosis in the glomeruli and intracapsular haemorrhage.

Progressive vascular degeneration brings in such episodes as cerebral haemorrhage, cardiac infarction and oedema of the lungs.

CLINICAL PICTURE.—Severe disabling symptoms suddenly appear in a middle-aged person previously apparently healthy.

(a) The manifestations are intense *headache* commencing on waking in the morning often frontal or in the vertex : *dyspnoea* exertional or may be paroxysmal and nocturnal may be with pulmonary oedema : blurring of *vision* : transient *paralysis*, *disorientation* may be with mental irritability, *convulsion* and *coma*. These may be reversible by treatment with hypotensive drugs upto a certain stage.

(b) *Haemorrhages* as epistaxis, haemoptysis and haematemesis are signs of severe hypertension.

(c) *Polyuria*, may be nocturnal is a frequent event. *Hcematuria* may be the sign of intense necrotising lesions in the kidneys.

(d) Abdominal, gall-bladder and testicular *pain* caused by focal vascular necrosis may occasionally be present.

PHYSICAL SIGNS.—(a) *Hypertension* is very marked : systolic pressure may reach or exceed 220 mm. and diastolic 120 mm. or higher which *remain steady* during the active stage of the disease. Heart is markedly hypertrophied and the superficial arteries are thickened and palpable like cords : may develop congestive failure or present signs of cardiac ischasmia.

(b) *Eyes : Papillcedema* is the characteristic diagnostic sign : this is bilateral and associated with retinal oedema, haemorrhages and exudates. Intensity of retinopathy has a bearing on survival rate.

(c) *Kidneys*.—In most cases urine has albumin and frequently red blood corpuscles and occasionally tube casts. Nitrogen retention is not a constant sign but this may be retained moderately ; in advanced stage, rapid retention.

TERMINATION.—This is a progressive disorder and in the absence of treatment, terminates if acute within a few months of the appearance of first symptoms : the average survival period is 1 to 2 years. Women usually have a longer period of longevity. The terminal events are often a combination of congestive failure with pulmonary oedema, uraemia, hypertensive encephalopathy and retinopathy.

DIAGNOSIS.—First point to decide whether hypertension is labile or persistent. Blood pressure is taken several times in the day, after night's sleep and during sleep after sedation with amytal. Blood pressure of femoral artery is also taken to exclude co-arcation of the aorta.

(i) Differential diagnosis between *benign* and *malignant hypertension* depends on the presence of papillcedema.

(ii) *Renal diseases*.—Only in the late stages of chronic nephritis malignant syndrome with papillcedema appears. Non-functioning or grossly deformed one kidney having similar manifestations is best diagnosed by a pyelogram. (iii) Intracranial new growth causes papillcedema but no cardiovascular signs.

ASSESSMENT OF PROGNOSIS.—A case of hypertension requires investigation of the family history and the past history of renal disease in the patient : his cardiovascular state (blood pressure especially the diastolic, left ventricular enlargement, presence of any myocardial ischffimic state and condition of the fundus oculi) and assessment of renal function. (The last is rapidly lowered in malignant hypertension).

A mild case of benign type with no symptoms, not much cardiac enlargement and no renal impairment and fundus oculi normal may carry on for many years provided kept under a controlled regime. But complications shorten longevity.

TREATMENT OF HYPERTENSION.—A patient *not having any symptoms* needs reassurance to allay the panic. Adequate mental and physical rest also a good period of sleep are essential : all these tend to lower the blood pressure. Long hours of

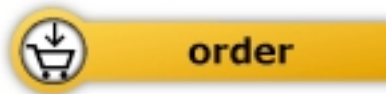

P.C. Majumdar, MD

[Bed-Side Medicine](#)

A Text-Book of Medicine. Clinical and Systematic

1340 pages, hb
publication 1979



More books on homeopathy, alternative medicine and a healthy life www.narayana-verlag.com